



## COMPARATIVE EXAMINATION OF CONVENTIONAL DIRECT SPUTUM AND INDIRECT SEDIMENTATION ON CYTOSPIN TUBERCULOSIS PATIENT SPUTUM SAMPLES

Widodo<sup>a\*)</sup>; Devi Etivia Purlinda<sup>b</sup>; Ahmad Riadi<sup>c</sup>

<sup>a,b,c</sup> *Department of Health Analyst ; Ministry of Health Semarang ; Wortel Monginsidi No. 115 ;  
Pedurungan ; Semarang 50192 ; Indonesia*

### Abstract

Microscopic examination of sputum using the Ziehl-Neelsen stain is the gold standard for Tuberculosis (TB), but it must be performed by experts with special skills. The purpose of this study is to accelerate the determination of the microscopic results using the Ziehl-Neelsen stain. This research is an experimental method in which the test sample is treated and the sputum sample is controlled with up to 25 samples. The method development is very important to increase the sensitivity and specificity of the results of TB examination using microscopes. This observation shows that the indirect cytospin method has a narrower reading range on a circle with a diameter of only 7 mm, making it easier for a bacterial count compared to the traditional direct method with a size of 2 x 3 cm oval shape. The results of the microscopic examination were 21 positive specimens and 4 negative specimens. Mycobacterium tuberculosis with Ziehl-Neelsen staining gave the same results with a sensitivity and specificity of 100%.

**Keywords:** *sputum; direct; indirect*

### 1. Introduction

The Mycobacterium tuberculosis (TB) complex is responsible for morbidity and mortality worldwide (Kurmi, Chaurasia, Goel, Joshi, & Kapoor, 2021). Delay in diagnosis can suspend the administration of appropriate treatment and be detrimental to patient outcomes (Angaali, Apparao Patil, & Dharma Teja, 2019). Bronchoalveolar flushing is performed as a better diagnostic measure for suspected cases of pulmonary TB when the sputum smear and culture results are negative (Mushtaq Ahmad et al., 2019).

Sputum microscopic examination for acid-fast bacilli is a simple and rapid test used to diagnose suspected infectious TB smears with

concentrated specimens using the membrane filter method to increase sensitivity (Anthwal et al., 2021) (Fennelly et al., 2012). Microscopic examination of sputum specimens using conventional techniques for TB screening has a weakness, one of which is the sensitivity value of the examination varies between 20% and 60% (Khutlang et al., 2010).

The sedimentation technique is one of the pre-analytical stages of TB examination. It is used for processing TB sputum before making smears, using sodium hydroxide (NaOCl) solution. The solution serves the need for laboratory safety during the pre-analytical process of sputum processing. The free chlorine content of NaOCl can inactivate microorganisms in clinical specimens including sputum specimens (Mindolli, Salmani, & Parandekar, 2013).

---

<sup>\*)</sup> Corresponding Author (Widodo)  
E-mail: widodo124@gmail.com

NaOCl solution is also suitable for removing mucus and saliva from phlegm particles, facilitating indirect inspection of sedimentation, maintaining morphology, and increasing staining on the bacterial cell wall to prepare clean sputum during microscopic observation of TB bacteria and to increase the examination sensitivity (G., Chandrasekaran, J., & B., 2017).

The use of cytospin in the manufacture of slide preparations makes it easier to work and shortens processing time with the same results with a small reading zone diameter, thus shortening processing and lowering infectious rates (Chen et al., 2012) (Imtiaz, Ikram, Zaman, Satti, & Sana, 2021).

The gold standard for TB diagnosis is bacterial culture examination. The assay is highly sensitive and detects up to 10 AFB/mL sputum, but the method is laborious and takes about 12 weeks to provide diagnostic results. The examinations also require more complex laboratory facilities, e.g. that provide culture Biosafety Level 3 (BSL-3), because these specimens are Mycobacterium TB whose handling and processing require a higher level of safety (Magalhães et al., 2018).

This research is aimed at finding differences in the results between the direct (conventional) and the indirect (Cytospin centrifugation) examinations on sputum specimens for the benefit of TB patients at Balkesmas Semarang.

## 2. Method

The experiment started with handling the test samples and controlling the sputum samples. Up to 25 samples of sputum samples at Balkesmas Semarang were taken using random sampling as a minimum number of samples to represent Negative, Positive, and Scanty results. Sputum specimens were collected and the smears were prepared and examined using the direct method (conventional) and the indirect method (sedimentation centrifugation or cytospin).

Conventionally, a smear is prepared for identification by making whorls flat and thin with a size of 2 x 3 cm, then stained using Ziehl Neelsen's method (G. et al., 2017) (Ludam & Jena,

2019) (Widodo, Irianto, & Pramono, 2017) (Widodo & Priyatno, 2020) (Zheng et al., 2016).

On the other hand, to prepare smears with the indirect (cytospin) method for Mycobacterium TB identification, the sputum was mixed with 2% NaOCl in a ratio of 1 to 3. All samples were used and allowed to rest for 20 minutes, then centrifuged to precipitates and discard the supernatant pellet or the precipitates. Next, a 0.5 ml of 4% NaOH solution was added to the precipitates, then another centrifugation was performed at 3000 rpm for 10 minutes with ELITech Cytospin within a chamber volume of 0.5 ml. The sample was then mounted to a glass object with a diameter of 7 mm, fixed, and then stained with Ziehl Neelsen's, 1% of carbolfuchsin, 3% of alcohol HCl, and 0.1% of methylene blue. Bacteria are pink while the background is blue (G. et al., 2017) (Imtiaz et al., 2021)(Kurmi et al., 2021)(Imtiaz et al., 2021)(Kurmi et al., 2021)(State, 2021).

**Tabel 1.** International Union Against Tuberculosis and Lung Diseases (IUATLD)

Reading under the microscope	Reporting Results
No AFB found in 100 fields of view	Neg.
1-9 AFB in 100 fields of view	Scanty
1-10 AFB in 1 fields of view	+1
10-99 AFB in 100 fields of view	+2
>10 AFB in 1 fields of view	+3

All of the preparations made were then observed directly using an objective lens microscope with 1000 times magnification by dripping immersion oil on the preparations to read the results of the acid-fast bacilli (AFB) number for identifying Mycobacterium TB (Imtiaz et al., 2021). The reading for the AFB results uses the scale published by the International Union Against Tuberculosis and Lung Diseases (IUATLD) in Table 1 (MacLean, Bigio, Singh, Klinton, & Pai, 2021) (WHO, 2020).

## 3. Result and Discussion

The examination of 25 samples shows 4 (16%) negative and 21 (84%) positive samples.

**Tabel 2.** Test Results Examination table comparing TB scales between the direct and the indirect tests of Mycobacterium TB

Direct	Indirect cytospin concentration					Total
	negative n (%)	Scanty n (%)	1 + n (%)	2 + n (%)	3 + n (%)	
Negative	4 (16)					4
Scanty		1(4)	3(12)		1(4)	5
1 +			3(12)			3
2 +			2(8)	3(12)	2(8)	7
3+				1(4)	5(20)	6
Total	4	1	8	4	8	25

Table 2. shows the results of the direct and indirect tests. Four specimens yielded the same, negative results between the two methods. Five scanty direct samples can be compared with the indirect results: 1 sample scanty, 3 samples (1+), and 1 sample (3+). This can happen because along the sampling process each sample volume is processed to obtain a precipitate and transported to the next process.


For the sample (1+), 3 specimens achieve the same result for both direct and indirect tests. The results of the sample (2+) for direct is 7 samples. The indirect test revealed comparative results of 2 samples (1+), 3 samples (2+), and 2 samples (3+). The 6 samples (3+) from the direct test can be compared to the indirect results: 1 sample (2+) and 5 samples (3+).

The difference between direct and indirect results is attributed to the volume of sputum collected, which is directly taken each by the size of small soybean seed, while in the indirect method, all samples are collected and then accommodated. Processing in the decontamination stage was carried out with NaOCl and centrifugation, while sedimentation is done using NaOH.

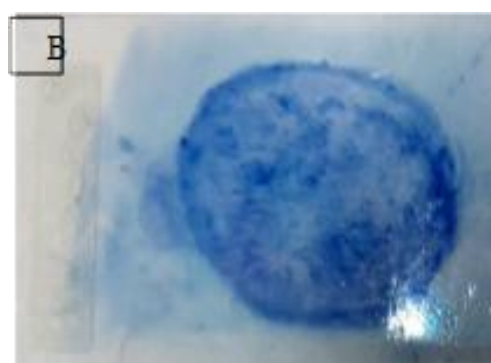So in this study, only one sample was wrong because the volume of the sample which was mixed with saliva during the concentration process resulted in a large number of bacteria in the indirect method. The preparations of the indirect and direct methods can be observed in the images below.

In Figure 1, the staining of the acid-resistant bacilli (Ziehl-Neelsen) uses Carbol-fuchsin alkaline. Decolorization with acid alcohol was sequentially performed to remove everything but the mycobacteria which retain/hold fast to the dye. Next, methylene blue is painted onto the samples to increase background contrast (Storch, 2018).

Indirect



Direct



**Figure 1.** Mixture preparation (A) with Indirect method using a 7 mm glass object and method (B) with Direct method using a flat and thin circle with a size of 2 x 3 cm.

Visually, the indirect painting results look cleaner because it has gone through several processes. The direct painting with a more blueish color, although it seems visually clear, cannot describe the results of the IUALTD Mycobacterium tuberculosis interpretation (WHO, 2020).

Using a Zeis digital microscope with a 1000X magnifying lens, with the help of Immersion Painting Oil, the degree of sensitivity and specificity of the method of direct and

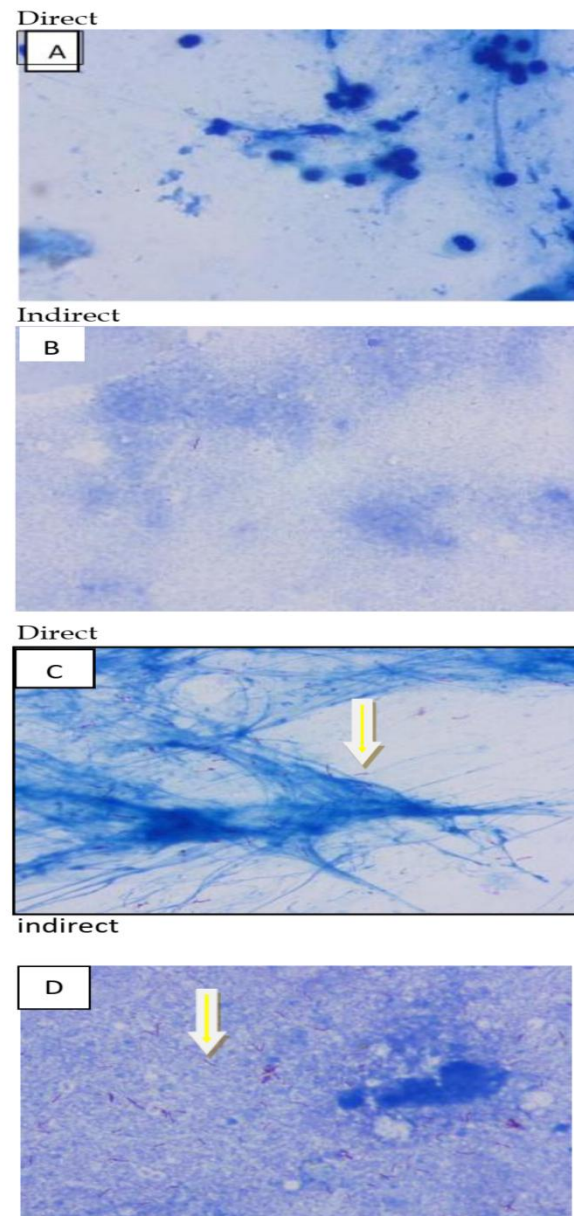
indirect microscopic examination of Mycobacterium TB can be observed. (Zingue, Weber, Soltani, Raoult, & Drancourt, 2018). As shown in Figures 2 A and C, with the conventional direct method the M.TB are shown as short rods, while in Figures 2 B and D with the indirect method they are shown as short rods but clustered.

The microscopic observations revealed that the cytospin method has the advantage of having narrower reading zones than that of the direct method, and accelerates the observation and calculation of the number of bacteria. Nevertheless, when developed by attaching a substance or specific antibodies against Mycobacterium TB, indirect slides still need an affixed egg albumin membrane for immobilization to get better results than that of the conventional direct method examination as the gold standard for microscopic TB diagnosis.

The results in table 3 indicate 100% of sensitivity, 100% of specificity, and 100% of accuracy values. This is a remarkable result compared to another study (Imtiaz et al., 2021) whose result indicates 68.3% sensitivity, 100% specificity, and overall diagnostic accuracy of 84.6%. Our experiment has shown that there was no difference in result between the direct method and the cytospin indirect method in Ziehl-Neelsen staining. This means a positive result on the direct examination will show as a positive result on the indirect method, and likewise with the negative results. For a laboratory diagnosis of Mycobacterium TB, sensitivity depends on the laboratory personnel's experience in diagnosing smears with Ziehl-Neelsen staining (Zingue et al., 2018). Improvement of image quality with a threshold setting on a trinocular microscope provides a brightness level of images on Mycobacterium TB (Kurmi et al., 2021).

The cytospin method significantly improved the detection with Ziehl-Neelsen stains when compared to the concentrated method. The experiment by Heemskerk et al., (2018) suggested there was no difference between the conventional and the cytospin techniques in their sensitivity, proposing values of 33.9% and 34.5% respectively for conventional ZN and modified ZN, despite G. et al.'s (2017) statement that conventional ZN staining was better than the modified ZN. In addition, a 2013

study by Uddin et al. (2013) revealed that concentrated technique increases the sensitivity of microscopy by up to 12%.



**Figure 2.** Morphology of Mycobacterium tuberculosis with Ziehl Neelsen colors A and B negative results Method direct and indirect. C and D result positively in the Direct and Indirect methods (observation magnification 1000 X trinocular microscope).

TB Detection Kit method for pulmonary TB diagnosis using a sputum smear technique increases the average results by 4% when compared to conventional methods (Heemskerk et al., 2018). Ahmad et al., (2021) stated that the ZN staining method has high specificity, but



moderate sensitivity when compared to GeneXpert MTB/RIF (Agrawal, et al., 2016); (Fouda et al., 2019).

**Table 3.** Comparison of the direct and indirect microscopy

		Direct		Total
		Standard Positive	Standard Negative	
Indirect	positive	21	0	21
	negative	0	4	4
		21	4	

The automatic detection method is used to reduce microbiological limitations in detecting Mycobacterium TB in terms of size, overlapping morphology, and difficulty in diagnosing the number of bacteria (Ibrahim et al., 2021). Culture remains the gold standard for diagnosing TB, although growth can take up to 6– 8 weeks. AFB is a rapid, simple, and inexpensive test in the early detection of TB cases but the accuracy of the results is low when compared to Lowenstein-Jensen (LJ) culture media, which is the gold standard for confirmation of TB (Ludam & Jena, 2019), (Roy & Gupta, 2022).

Our method offers an advantage in the laboratory safety for microscopic Mycobacterium TB examination, minimizing infection risk for the laboratory personnel. However, one needs to invest more in the pieces of equipment used in this method. This study has limitations in terms of the sparse sample and the sample number needs to be increased to confirm the method's effectiveness.

#### 4. Conclusion and Suggestions

Our study found no difference between direct and indirect Mycobacterium TB sputum examinations. The results have indicated the indirect cytospin method gives advantages of a narrower reading zone, an acceleration of observation and bacterial count, and a better level of security with decontamination of MTB as compared to the conventional direct method. Further research is expected to use a larger number of negative and scanty samples.

#### 5. Acknowledgments

I would like to thank the Director of the Health Ministry Polytechnic of Semarang, the Semarang Ministry of Health Polytechnic DIPA for the research funding, and Elly Karina, Nur

Jani, and Tri Sugiatmini for assisting the research process.

#### 6. References

- Agrawal, M., Bajaj, A., Bhatia, V., & Dutt, S. (2016). Comparative study of GeneXpert with ZN stain and culture in samples of suspected pulmonary tuberculosis. *Journal of Clinical and Diagnostic Research*, 10(5), DC09-DC12.  
<https://doi.org/10.7860/JCDR/2016/18837.7755>
- Ahmad, Mujeeb, Stanikzai, M. H., Rahimy, N., Wasiq, A. W., & Sayam, H. (2021). Diagnostic Accuracy of Ziehl-Neelsen Smear Microscopy in Comparison with GeneXpert in Pulmonary Tuberculosis: A Multi-Center Study in Kandahar Province, Afghanistan. *Asian Journal of Medicine and Health*, (March), 1 – 7.  
<https://doi.org/10.9734/ajmah/2021/v19i230299>
- Ahmad, Mushtaq, Ibrahim, W. H., Sarafandi, S. Al, Shahzada, K. S., Ahmed, S., Haq, I. U., ... Sattar, H. A. (2019). Diagnostic value of bronchoalveolar lavage in the subset of patients with negative sputum/smear and mycobacterial culture and suspicion of pulmonary tuberculosis. *International Journal of Infectious Diseases*, 82, 96 – 101.  
<https://doi.org/10.1016/j.ijid.2019.03.021>
- Angaali, N., Apparao Patil, M., & Dharma Teja, V. (2019). Detection of Mycobacterium tuberculosis - Microscopy to Molecular Techniques at the Tertiary Care Hospital in Telangana. *Iranian Journal of Medical Microbiology*, 13(3), 175 – 179.  
<https://doi.org/10.30699/ijmm.13.3.175>
- Anthwal, D., Gupta, R. K., Gomathi, N. S., Tripathy, S. P., Das, D., Pati, S., ... Tyagi, J. S. (2021). Evaluation of 'TBDetect' sputum microscopy kit for improved detection of Mycobacterium tuberculosis: a multi-centric validation study. *Clinical Microbiology and Infection*, 27(6), 911.e1-911.e7.  
<https://doi.org/10.1016/j.cmi.2020.08.020>
- Chen, P., Shi, M., Feng, G. D., Liu, J. Y., Wang, B. J., Shi, X. D., ... Zhao, G. (2012). A highly efficient Ziehl-Neelsen stain: Identifying de novo intracellular Mycobacterium tuberculosis and improving detection of extracellular M. tuberculosis in cerebrospinal fluid. *Journal of Clinical*

- Microbiology*, 50(4), 1166 – 1170.  
<https://doi.org/10.1128/JCM.05756-11>
- Fennelly, K. P., Morais, C. G., Hadad, D. J., Vinhas, S., Dietze, R., & Palacib, M. (2012). The small membrane filter method of microscopy to diagnose pulmonary tuberculosis. *Journal of Clinical Microbiology*, 50(6), 2096 – 2099.  
<https://doi.org/10.1128/JCM.00572-12>
- Fouda, M. E., Gwad, E. R. A., Fayed, S. M., Kamel, M. H., & Ahmed, S. A. (2019). *Egyptian Journal of Medical Microbiology A Study of the Added Value of Xpert MTB / RIF Assay for Assessment of Pulmonary Tuberculosis Transmission Risk ORIGINAL ARTICLE A Study of the Added Value of Xpert MTB / RIF Assay for Assessment of Pulmonary Tuberculosis Transmission Risk*. (September).
- G., A. K., Chandrasekaran, S., J., V., & B., V. K. (2017). Bleach method in comparison with NALC-NaOH specimen processing method for the detection of mycobacterium in sputum specimen. *International Journal of Research in Medical Sciences*, 5(9), 3865.  
<https://doi.org/10.18203/2320-6012.ijrms20173645>
- Heemskerk, A. D., Donovan, J., Thu, D. D. A., Marais, S., Chaidir, L., Dung, V. T. M., ... Thwaites, G. E. (2018). Improving the microbiological diagnosis of tuberculous meningitis: A prospective, international, multicentre comparison of conventional and modified Ziehl – Neelsen stain, GeneXpert, and culture of cerebrospinal fluid. *Journal of Infection*, 77(6), 509 – 515.  
<https://doi.org/10.1016/j.jinf.2018.09.003>
- Ibrahim, A. U., Guler, E., Guvenir, M., Suer, K., Serte, S., & Ozsoz, M. (2021). Automated detection of Mycobacterium tuberculosis using transfer learning. *Journal of Infection in Developing Countries*, 15(5), 678 – 686.  
<https://doi.org/10.3855/JIDC.13532>
- Imtiaz, A., Ikram, A., Zaman, G., Satti, L., & Sana, F. (2021). *Evaluation of modified cyto spin slide microscopy for detection of acid fast bacilli in broncho alveolar lavage fluid for diagnosis of pulmonary tuber*. 71(3), 920–923.
- Khutlang, R., Krishnan, S., Dendere, R., Whitelaw, A., Veropoulos, K., Learmonth, G., & Douglas, T. S. (2010). Classification of mycobacterium tuberculosis in images of ZN-stained sputum smears. *IEEE Transactions on Information Technology in Biomedicine*, 14(4), 949 – 957.  
<https://doi.org/10.1109/TITB.2009.202833>
- 9
- Kurmi, Y., Chaurasia, V., Goel, A., Joshi, D., & Kapoor, N. (2021). Tuberculosis bacteria analysis in acid-fast stained images of sputum smear. *Signal, Image and Video Processing*, 15(1), 175 – 183.  
<https://doi.org/10.1007/s11760-020-01732-1>
- Ludam, R., & Jena, B. (2019). Microscopic versus culture methods for diagnosis of Mycobacterium tuberculosis: Our experience. *International Journal of Advanced Research in Medicine*, 1(2), 109 – 111.  
<https://doi.org/10.22271/27069567.2019.v1.i2b.93>
- MacLean, E., Bigio, J., Singh, U., Kinton, J. S., & Pai, M. (2021). Global tuberculosis awards must do better with equity, diversity, and inclusion. *The Lancet*, 397(10270), 192–193.  
[https://doi.org/10.1016/S0140-6736\(20\)32627-1](https://doi.org/10.1016/S0140-6736(20)32627-1)
- Magalhães, J. L. de O., Lima, J. F. da C., de Araújo, A. A., Coutinho, I. O., Leal, N. C., & de Almeida, A. M. P. (2018). Microscopic detection of mycobacterium tuberculosis in direct or processed sputum smears. *Revista Da Sociedade Brasileira de Medicina Tropical*, 51(2), 237 – 239.  
<https://doi.org/10.1590/0037-8682-0238-2017>
- Mindolli, P. B., Salmani, M. P., & Parandekar, P. K. (2013). Improved diagnosis of pulmonary tuberculosis using bleach microscopy method. *Journal of Clinical and Diagnostic Research*, 7(7), 1336 – 1338.  
<https://doi.org/10.7860/JCDR/2013/6152.3189>
- Roy, R. Das, & Gupta, S. Das. (2022). *A Comparative Study of Cartridge - Based Nucleic Acid Amplification Test and Ziehl – Neelsen Stain with Culture on Lowenstein – Jensen Media as Gold Standard for the Diagnosis of Pulmonary Tuberculosis*. 39–42.  
<https://doi.org/10.4103/ijrc.ijrc>
- State, O. (2021). *Efficacy of Fluorescence Light Emitting Diode ( LED ) Microscopy for Detection of Mycobacterium Tuberculosis in Sputum of Patients Attending a Tertiary Hospital in Osogbo*. 3(1).
- Storch, G. A. (2018). Chapter 170 - Diagnostic Microbiology. In *Nelson Textbook of Pediatrics, 2-Volume Set (Twentieth)*. Elsevier Inc.  
<https://doi.org/10.1016/B978-1-4557-7566-8.00170-8>
- Uddin, M. K. M., Chowdhury, M. R., Ahmed, S.,

- Rahman, M. T., Khatun, R., Van Leth, F., & Banu, S. (2013). Comparison of direct versus concentrated smear microscopy in detection of pulmonary tuberculosis. *BMC Research Notes*, 6(1).  
<https://doi.org/10.1186/1756-0500-6-291>
- WHO. (2020). Tuberculosis Reports. In *The Lancet* (Vol. 188).  
[https://doi.org/10.1016/S0140-6736\(00\)58733-9](https://doi.org/10.1016/S0140-6736(00)58733-9)
- Widodo, W., Irianto, A., & Pramono, H. (2017). Karakteristik Morfologi Mycobacterium tuberculosis yang Terpapar Obat Anti TB Isoniazid (INH) secara Morfologi. *Biosfera*, 33(3), 109.  
<https://doi.org/10.20884/1.mib.2016.33.3.316>
- Widodo, W., & Priyatno, D. (2020). DETECTION OF THE RESISTANCE OF MYCOBACTERIUM TUBERCULOSIS FROM SPECIMENS WITH TB PATIENTS IN SEMARANG BALKESMAS. *Jurnal Riset Kesehatan*.  
<https://doi.org/10.31983/jrk.v9i1.5583>
- Zheng, L. H., Jia, H. Y., Liu, X. J., Sun, H. S., Du, F. J., Pan, L. P., ... Zhang, Z. D. (2016). Modified cytospin slide microscopy method for rapid diagnosis of smear-negative pulmonary tuberculosis. *International Journal of Tuberculosis and Lung Disease*, 20(4), 456 – 461.  
<https://doi.org/10.5588/ijtld.15.0733>
- Zingue, D., Weber, P., Soltani, F., Raoult, D., & Drancourt, M. (2018). Automatic microscopic detection of mycobacteria in sputum: a proof-of-concept. *Scientific Reports*, 8(1), 1 – 6.  
<https://doi.org/10.1038/s41598-018-29660-8>