



Usage of HU Thresholding in Carotid-Cerebral CT Angiography: A Qualitative Study

I Putu Eka Juliantara¹, Angga Pratama²

¹AKTEK Radiodiagnostik dan Radioterapi Bali

²Rumah Sakit Premier Bintaro

Corresponding author: I Putu Eka Juliantara

Email: ekaj.atro@gmail.com

ABSTRACT

Background: CT scans with contrast media administration are commonly used to confirm the presence of pathology in the blood vessels of the brain, especially in the assessment of aneurysm pathology. The development of CT-helical image acquisition techniques has enabled neuroradiologists to evaluate brain aneurysms accurately and efficiently. While magnetic resonance (MR) angiography is also useful in the diagnosis of brain aneurysms, it is generally more time-consuming and sensitive to movement artifacts than 3D CTA.

Methods: This qualitative research with an observational approach aims to determine the management of carotid-cerebral CTA artery examination in Premier Bintaro Hospital. Unstructured interviews and documentation were used to gather data.

Results: The study found that Premier Bintaro Hospital uses a bolus tracking scanning technique with ROI monitoring of the Carotid Internal Artery and triggers a peak enhancement of 100-120 HU to produce optimal enhancement in the Circulus of Willis (CoW) region as Volume of Investigation (VOI) in cerebral Angiography CT-Scan. Post-processing is done by displaying images ranging from axial pre-contrast, axial post-contrast, study (pathology), MIP (Axial, coronal, sagittal), Region of Interest MIP (structure labeling), 3D VRT-bone removal.

Conclusion: The scanning technique with bolus tracking and ROI monitoring of the Internal Carotid Artery and using triggering of 100-120 HU as a peak enhancement on ROI monitoring is an effective method for displaying arterial artery images. This method allows for easy post-processing without reducing the quality and related image information.

Keywords: CTA, Carotid-Cerebral Artery, HU threshold, Peak Enhancement

Introduction

A cerebral aneurysm (brain aneurysm) is a disorder in which there is weakness in the walls of the blood vessels of the brain, both arteries and veins (tunica media and tunica intima of arteries and veins) which causes localized swelling of the blood vessels of the brain(1). Cerebral aneurysm generally affects adults aged over 20 years with a percentage of 6% worldwide and a mortality rate

of more than 50%. An aneurysm causes symptoms after the age of 40-60 years. Adult women have more cerebral aneurysms than adult men (3:2). In children it is usually caused by events after trauma or fungus. While in adults it is caused by a degenerative process(2,3).

Cerebral aneurysms rarely cause symptoms, unless they enlarge and press on one of the nerves in the brain, giving symptoms as a

depressed brain nerve disorder. Aneurysms that are small and non-progressive, will cause little or no symptoms(4). Early signs can be minutes to weeks before the aneurysm ruptures. Radiological examination is a very important process in diagnosing the location, size, and type of aneurysm that occurs(2,5).

Imaging techniques obtained in patients with brain aneurysms are becoming increasingly sophisticated. As a result, radiologists can interpret this case in a unique variety of ways to report relevant findings and make recommendations that may have a significant impact on patient care. Cerebral angiography is an important technique in diagnostic imaging and preoperative evaluation of brain aneurysms(5). However, cerebral angiography is an invasive procedure and carries a risk of certain complications. A substitute modality to be able to assess the pathological process of an aneurysm is to apply to image using a Computed tomography (CT) scan(6–9).

CT scan with the application of contrast media has been used to confirm the presence of aneurysms in the brain. The high accuracy and fast scanning times produced by CT scans make this modality the first choice in assessing the pathology of aneurysms in the brain. Technological advances as well as the development of CT-Scan image acquisition techniques in helical CT have enabled neuroradiologists to evaluate brain aneurysms in a short time(10,11). Magnetic resonance (MR) angiography has also been reported to be useful in the diagnosis of brain aneurysms(12,14), but generally more time-consuming than 3D CTA, and MRI is very sensitive to movement artifacts. In addition, some aneurysms are not well demonstrated by MR angiography because of turbulent or slow vascular flow(12,13,15).

Methods

This research is a qualitative study with an observational approach that aims to determine the procedure for examining the Carotid-Cerebral artery CTA at Premier Bintaro Hospital. Three patients were examined for Carotid-Cerebral Artery CTA at the Radiology Unit of Premier Bintaro Hospital as a related study subject. 1 radiologist and 1 radiographer as respondents to complete observations about the management of

related examinations. Unstructured interviews and documentation were used as research instruments to complete the required data.

Results and Discussion

The Cerebral Angiography CT-Scan examination technique at Premier Bintaro Hospital has the same stages as the existing theory, including patient preparation, tool preparation, protocol selection, scanning parameter settings, up to the post-processing to produce informative images for interpretation by the radiologist. Those stages are explained in more detail as follows.

Patient Preparation

Preparations that must be made by the patient before carrying out the examination are checking of urea and creatinine to determine the value of the Glomerular Filtrations Rate (GFR) as a reference for the patient's kidney function. Patients / Family Patients complete informed consent for the approval of the actions taken. In addition, officers also evaluate the medical history and allergies of patients such as allergies to contrast media and patients are given anti-histamine drugs if needed. It is not required to fast on the CABERIS CTA examination, but to prevent reflux it is recommended for fasting 3-4 hours before the examination.

Tools Preparation

There are several tools that must be prepared in carrying out a CT-Scan of Cerebral Angiography, including:

1. CT-Scan 128 Slices
2. Automatic injectors
3. Syringe Injector
4. Iodine based Contrast Media 350-370mg/ml (1-2cc/Kg)
5. Syringe 1 cc
6. IV-line No. 20
7. NaCl 50 ml
8. Infuse Set
9. Micropore, alcohol swab, Plaster
10. Y Connector tube
11. Film 14x17 cm
12. Printer Dry-View

Several tools such as leg fixation, pillows, blankets are needed to keep the patient comfortable during the examination. Make sure

the CT-Scan Tool is ready to scan (do check-ups, air calibration and other QC procedures).

Examination Procedure

The inspection procedure carried out after the preparation is complete is:

1. Patient Registration

Patient registration was done by placing an order for an examination through the RIS system at Premier Bintaro Hospital (Trakcare). The PACS system that has been implemented at Premier Bintaro Hospital allows Radiology requests at RIS to be integrated into the CT-Scan modality so that registration is done automatically. The officer double cross-checks the patient's identity by asking for the name and date of birth and checking the patient's bracelet.

2. Patient Positioning

The patient is instructed to lay on his/her back (supine) in a head first position with both hands at the sides of the body. Set the inner laser 2 cm above the Vertex, and the coronal laser at 2 cm of Meatus Acusticus Externa (MAE).

3. Protocol Selection

Click Supine and Head first, and select CT "Angiography Cerebralis" as the scanning protocol used. Furthermore, setting the appropriate scanning parameters to get optimal enhancement on Circulus of Willis (CoW).

4. Scanning process

The scanning process is carried out after determining the protocol used, as well as ensuring that the parameters are appropriate and can produce an optimal image. There are four scans carried out which include the topogram, pre-contrast scanning, CTA scanning, Vein Phase scanning.

5. Post Processing

This procedure is carried out after the scan is complete. Several techniques and parameters are selected in post processing to get the optimal image like 2D and 3D Volume rendering, Maximum Intensity Projection

(MIP), Bone Removal Application, and others.

Scanning Parameter

Of the four types of scanning carried out, each type of scanning has different parameters to maximize the image formed according to the purpose of doing the scanning, including:

1. Scanogram/Topogram

- a) kV: 80; 50 mA
- b) scan time: 5.4 s
- c) FOV: 256 mm

2. Brain Pre and Post Contrast (vein phase)

- a) kV = 80 kV; mA = AUTO mA
- b) scan time pre-CM: 5.4 s
- c) scan time post-CM: 3.2 s
- d) FOV: 200 mm
- e) rotation time: 0.35 s
- f) slice thickness: 4 mm (2 mm)
- g) slice collimation: 16x0,75 mm
- h) increment: 1.25 mm (1 mm)
- i) WW 150; WL 40
- j) Algorithm: soft tissue

3. Cerebral-CTA Parameter

- a) Triggering: 100-120 HU
- b) ROI: A. Carotid Interna
- c) Flow Rate: 3.5 ml/s
- d) CM volume: 370/80ml
- e) Saline: 30ml

Post Processing

The process carried out before being ready to be analyzed by the radiologist is to carry out the reconstruction and selection of the best image using post-processing techniques such as Multi Planar Reformatting (MPR), 2D and 3D Volume Rendering, Maximum Intensity Projection (MIP).

The first thing to do is do a reconstruction of the slice acquisition that has been formed by making it thinner to ensure the 3D resolution produced is better for reformatting and rendering. The reconstruction parameter carried out is as follows:

- a) Reconstruction: Soft Tissue
- b) Slice Thickness: 0.75mm
- c) Slice Increment: 0.7 mm
- d) Kernel: B31s Medium Smooth+
- e) Window: mediastinum
- f) Image Order: Craniocaudal

Pre-contrast scanning, post-contrast, and CTA scanning is carried out in this reconstruction to be reprocessed in the MPR along with the applications in it. In CTA scanning, several stages are carried out, such as:

1. Maximum Intensity Projection (MIP)

MIP is made to show the focused intensity of contrast enhancement in the vascular system of the brain without deleting/removal to other structures around it. MIP is done by adjusting the desired intensity level of about 15-20 mm on each slice (axial, coronal, and sagittal). MIP can also be used to display specific vascular structures in a particular region/area by doing a little tweaking of slice orientation to get a clear-cut image of a blood vessel area without the intervention of other structures around it. In MIP, measurements can also be made in the form of the size and the location of the pathology, the location of the pathology can be displayed in various orientation slices (MIP axial, coronal, and sagittal).

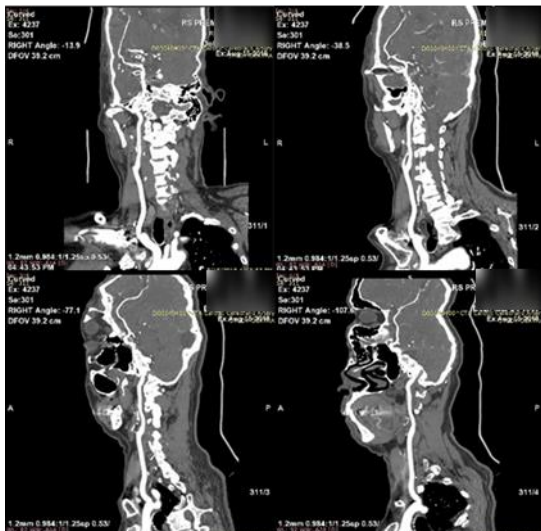


Figure 1. An example of a Cerebral CTA MIP image, is on the right carotid artery.

2. 3D Volume rendering Technique (VRT)

VRT provides flexibility in carrying out post-processing, especially in displaying three-dimensional images of blood vessels to assess the location and size of abnormalities in multidirectional (various directions) without the intervention of other structures around it. The VRT used is assisted with Bone Removal

facilities that can be done both manually (cropping) or automatic bone removal depending on the applications available in modality. In this case, Bone Removal is carried out using the applications that available on the PACS system to do Express Bone Removal on the neck and head.

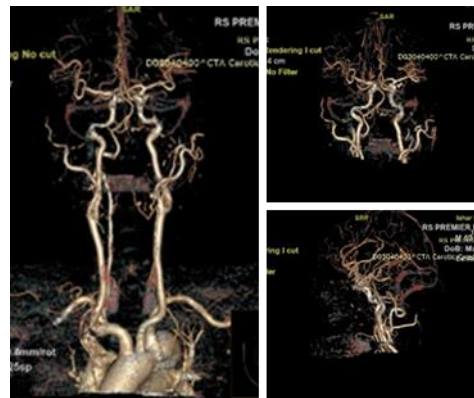


Figure 2. VRT view of the Carotid-Cerebral CTA from several angles.

A CT-Scan examination with the application of contrast media requires an accurate calculation of both the concentration of the contrast media given and the flow rate to be applied(5,16). These two things depend on the type of blood vessels being examined and the ability of the modality to do two fast scans. Brain blood vessels incorporated in the Circulus of Willis have a high flow rate due to the location of blood vessels that are very close to the center of the heart and have a fairly small caliber (13). So, it takes the right time and synchronous between peak enhancement of contrast media administration with detection carried out by CT-Scan modality(8).

A Multidetector/slices CT scan is a sophisticated modality equipped with a multi-detector so that it can provide a multi slices image in one rotation(17,18). Detectors that are not enough to make CT tools have limited rotation speed, which will impact on a long scan of time in reaching a volume of investigation (VOI)(7,19,20). This will be able to affect the

peak enhancement of contrast media administered if no appropriate parameter arrangements are made. In this case, the CTA Cerebral examination at the Premier Bintaro Hospital was carried out by putting the Region of Interest (ROI) for the Triggering Monitor as high as the Carotid Interna arteries. This is done to be able to ensure the VOI can be covered in a short scanning time and will have implications for the optimal enhancement of contrast media marked by Pure Artery Appearance. However, the laying of ROI in the internal carotid arteries was also followed by setting the Triggering HU of 100-120(21–23).

The achievement of optimal enhancement on VOI, it will make it easier for the radiographer to do post-processing both MPR, MIP, 2D and 3D VRT, and Bone Removal(24). The number of stages carried out on post processing is carried out to ensure the image received by the radiologist is an image with complete information by displaying images ranging from axial pre-contrast, axial post-contrast, study (pathology), MIP (axial, coronal, sagittal), MIP Region of Interest (specific structure-labelling), 3D VRT-Bone Removal. The display of various types of images is expected to help radiologists in diagnosing abnormalities that occur precisely and accurately(25,26).

Conclusion

Scanning with bolus tracking and ROI monitoring on the Internal Carotid Artery and using triggering of 100-120 HU as peak enhancement on ROI monitoring can display arterial images very well so that post-processing can be carried out (axial pre and post contrast), pathological study, MIP of ROI, 3D VRT-Bone Removal) easily without compromising quality and related image information.

References

1. Mack PF. Cerebral aneurysm. Yao Artusio's Anesthesiol Probl Patient Manag Seventh Ed. 2012;552–75.
2. Marco R. Pathogenesis, Diagnosis, and Treatment of the Cerebral Aneurysm. J Neurol Neurophysiol [Internet]. 2021;12(8):550. Available from: [https://www.iomcworld.org/open-](https://www.iomcworld.org/open-access/pathogenesis-diagnosis-and-treatment-of-the-cerebral-aneurysm-83456.html)

3. Vega J. What Is a Brain Aneurysm? [Internet]. 2021. p. 7. Available from: www.verywellhealth.com
4. Etminan N, Rinkel GJE. Cerebral aneurysms: Cerebral aneurysm guidelines-more guidance needed. Nat Rev Neurol [Internet]. 2015;11(9):490–1. Available from: <http://dx.doi.org/10.1038/nrneurol.2015.146>
5. Hacin-Bey L, Provenzale JM. Current imaging assessment and treatment of intracranial aneurysms. Am J Roentgenol. 2011;196(1):32–44.
6. Mallouhi A, Felber S, Chemelli A, Dessl A, Auer A, Schocke M, et al. Detection and characterization of intracranial aneurysms with MR angiography: Comparison of volume-rendering and maximum-intensity-projection algorithms. Am J Roentgenol. 2003;180(1):55–64.
7. de Figueiredo GN, Ertl-Wagner B. MDCT in neurovascular imaging. Med Radiol. 2019;185–205.
8. Toth G, Cerejo R. Intracranial aneurysms: Review of current science and management. Vasc Med (United Kingdom). 2018;23(3):276–88.
9. Maupu C, Lebas H, Boulaftali Y. Imaging Modalities for Intracranial Aneurysm: More Than Meets the Eye. Front Cardiovasc Med. 2022;9(February):1–9.
10. Shin JH, Lee HK, Choi CG, Suh DC, Lim TH, Kang W. The Quality of Reconstructed 3D Images in Multidetector-Row Helical CT: Experimental Study Involving Scan Parameters. Korean J Radiol. 2002;3(1):49–56.
11. Azhari S, Nayeb Aghaei H, Ghanaati H, Firouznia K, Zandi S. The diagnostic value of CT angiography in the diagnosis of residual aneurysm after brain aneurysm surgery. Iran J Radiol. 2018;15(1).

12. Paula B. Imaging of the Brain After Aneurysmal Subarachnoid Hemorrhage. 2010.
13. Cao X, Zeng Y, Wang J, Cao Y, Wu Y, Xia W. Differentiation of Cerebral Dissecting Aneurysm from Hemorrhagic Saccular Aneurysm by Machine-Learning Based on Vessel Wall MRI: A Multicenter Study. *J Clin Med.* 2022;11(13).
14. Samaniego EA, Roa JA, Hasan D. Vessel wall imaging in intracranial aneurysms. *J Neurointerv Surg.* 2019;11(11):1105–12.
15. Howard BM, Hu R, Barrow JW, Barrow DL. A comprehensive review of imaging of intracranial aneurysms and angiographically negative subarachnoid hemorrhage. *Neurosurg Focus.* 2019;47(6):1–13.
16. Paramount. Computed Tomography (CT) and Computed Tomography Angiography (CTA) Scans. 2021.
17. Prokop M, Michael G. Spiral and Multislice Computed Tomography of the Body . Stuttgart: Thieme; 2011.
18. Flohr TG, Schaller S, Stierstorfer K, Bruder H, Ohnesorge BM, Schoepf UJ. Multi-detector row CT systems and image-reconstruction techniques. *Radiology.* 2005;235(3):756–73.
19. Bruening R, Kuettner A, Flohr T. Protocols for multislice CT. *Protocols for Multislice CT.* 2006. 1–293 p.
20. Elnour H, Ahmed Hassan H, Mustafa A, Osman H, Alamri S, Yasen A. Assessment of Image Quality Parameters for Computed Tomography in Sudan. *Open J Radiol.* 2017;07(01):75–84.
21. Park S, Jang M, Lee K, Choi H, Lee Y, Park I, et al. Optimal placement of the region of interest for bolus tracking on brain computed tomography angiography in beagle dogs. *J Vet Med Sci.* 2021;83(8):1196–201.
22. Huang RY, Chai BB, Lee TC. Effect of region-of-interest placement in bolus tracking cerebral computed tomography angiography. *Neuroradiology.* 2013;55(10):1183–8.
23. Giffin NJ, Goadsby PJ. Basilar artery aneurysm with autonomic features: An interesting pathophysiological problem. *J Neurol Neurosurg Psychiatry.* 2001;71(6):805–8.
24. Karamessini MT, Kagadis GC, Petsas T, Karnabatidis D, Konstantinou D, Sakellaropoulos GC, et al. CT angiography with three-dimensional techniques for the early diagnosis of intracranial aneurysms. Comparison with intra-arterial DSA and the surgical findings. *Eur J Radiol.* 2004;49(3):212–23.
25. Vereniging KB, Universitair S, Antwerpen Z, Mulkens T, Hart H, Lier Z, et al. CT angiography : Basic principles and post- processing applications PROCEEDINGS OF THE VASCULAR IMAGING SYMPOSIUM VISA-2003 ., 2003;(May 2016).
26. Yoon NK, McNally S, Taussky P, Park MS. Imaging of cerebral aneurysms: a clinical perspective. *Neurovascular Imaging [Internet].* 2016;2(1):1–7. Available from: <http://dx.doi.org/10.1186/s40809-016-0016-3>